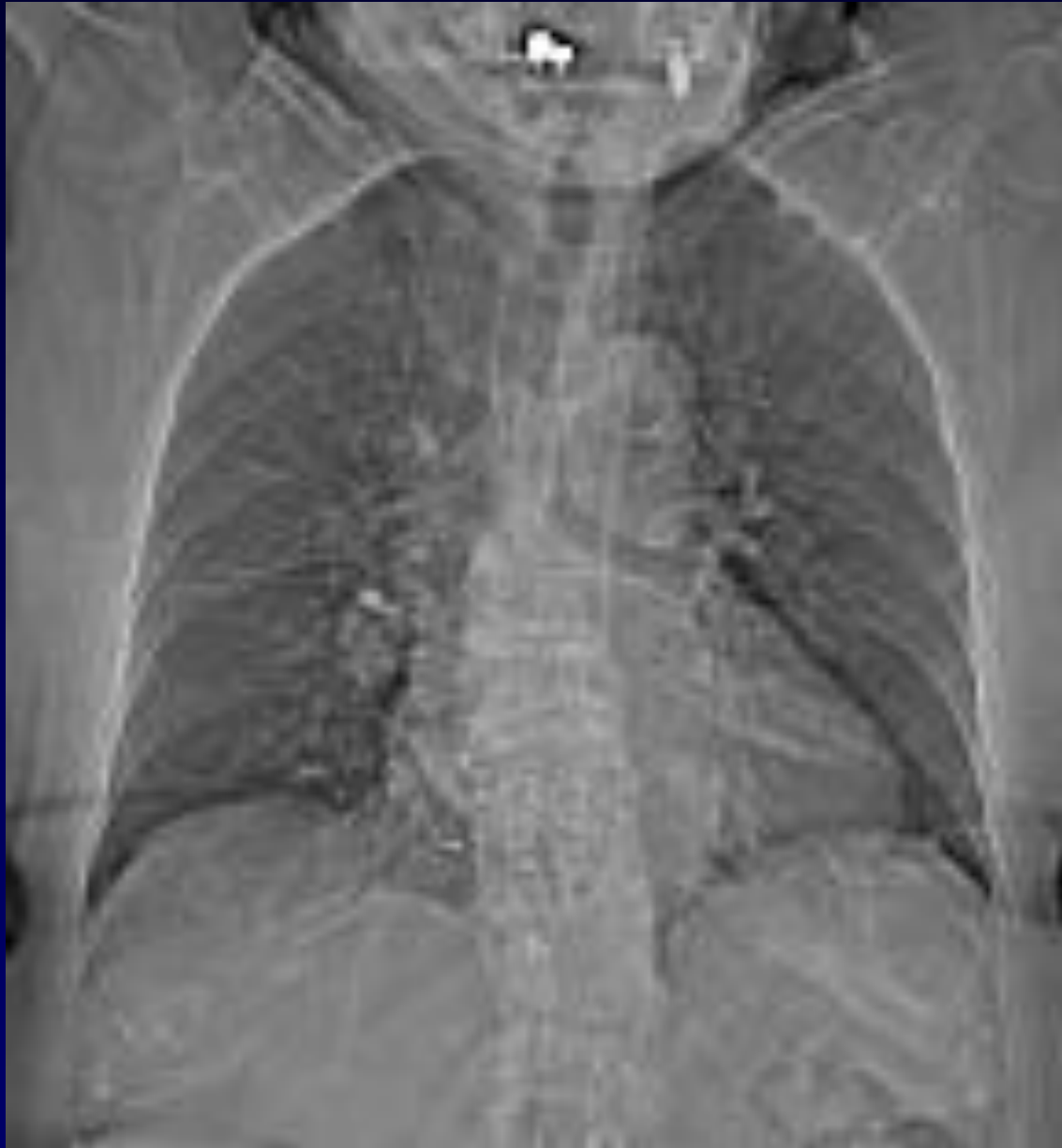



J. GIRON – P. FAJADET

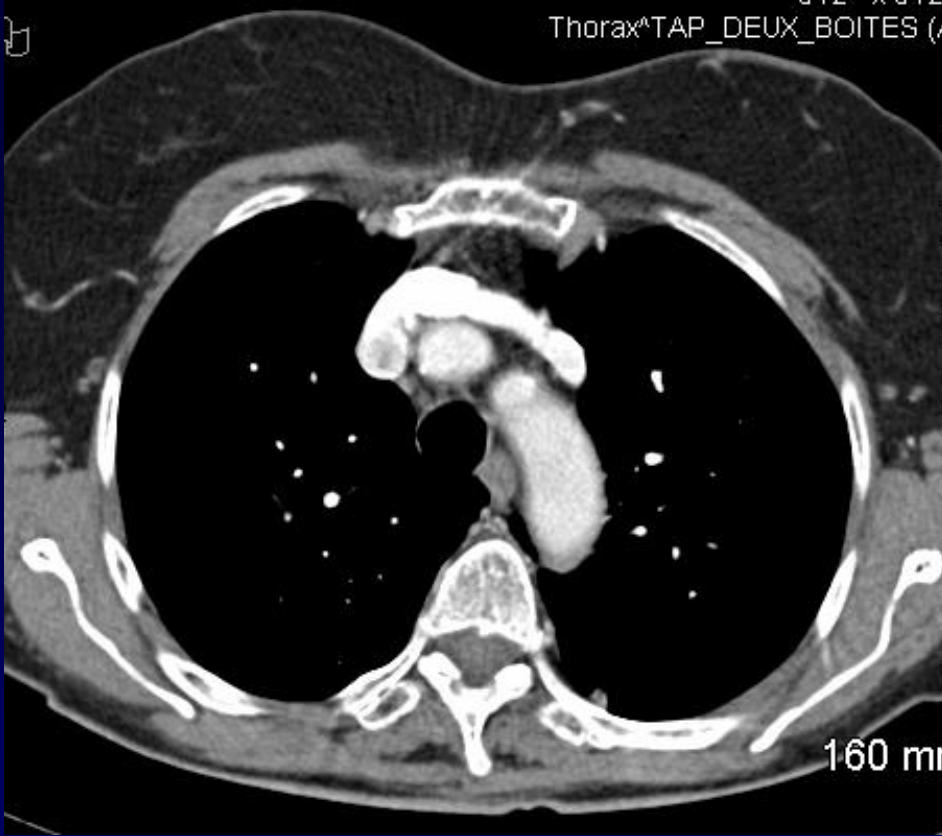
F, 65ans

DECOUVERTE FORTUITE



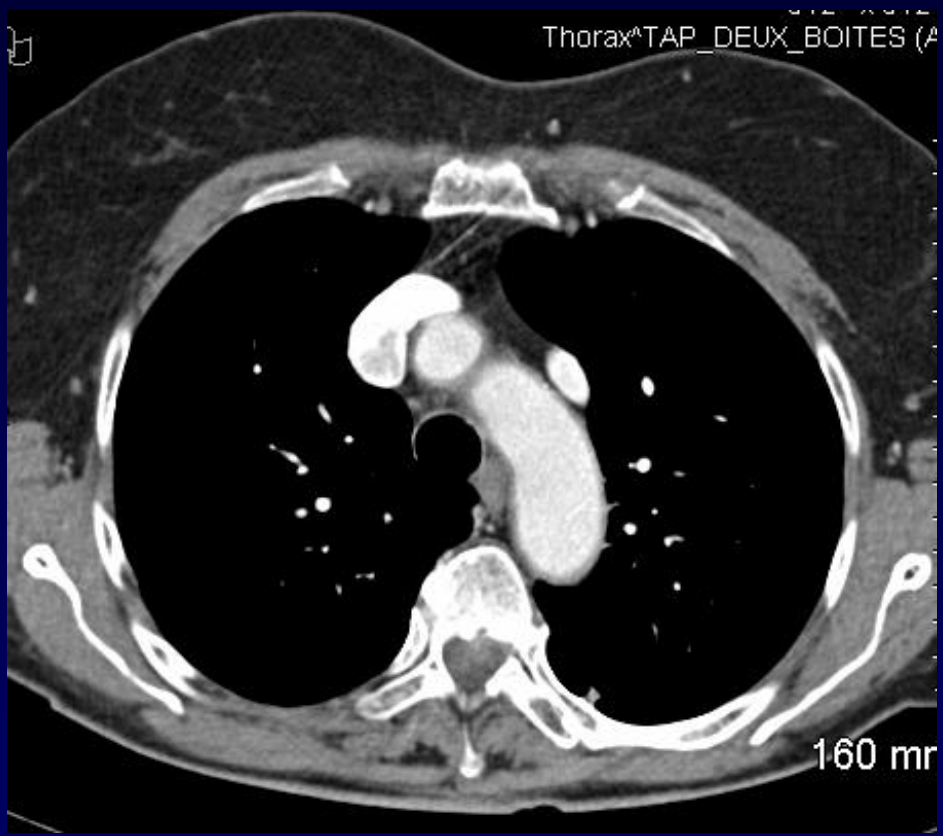


Thorax^TAP_DEUX_BOITES (A

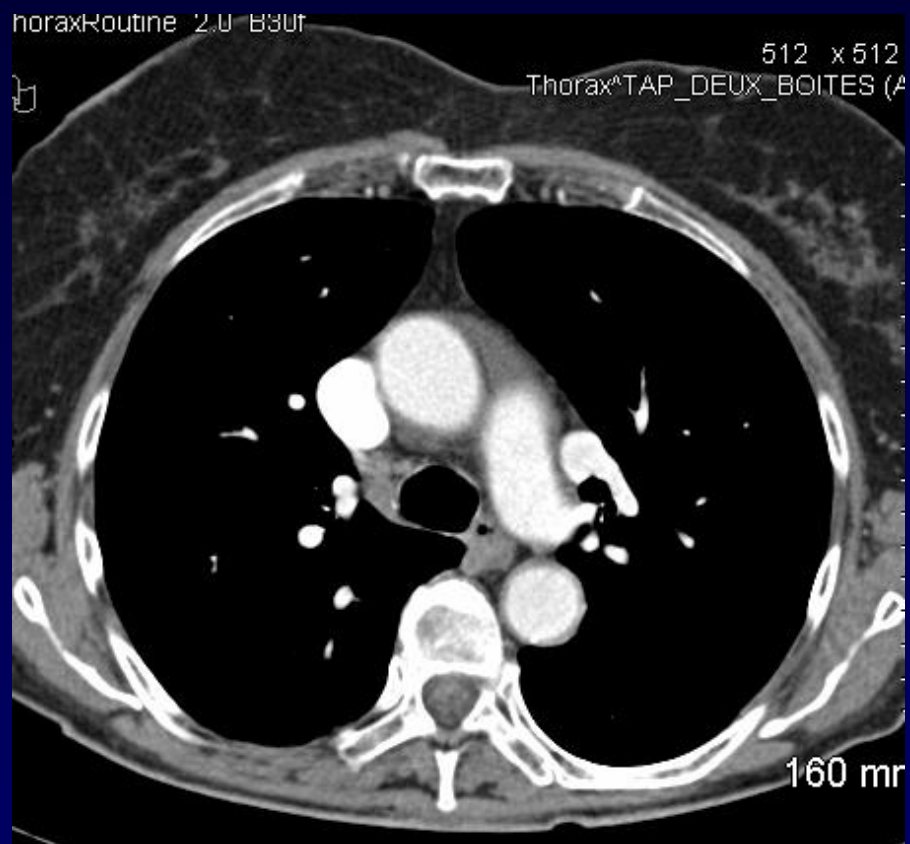
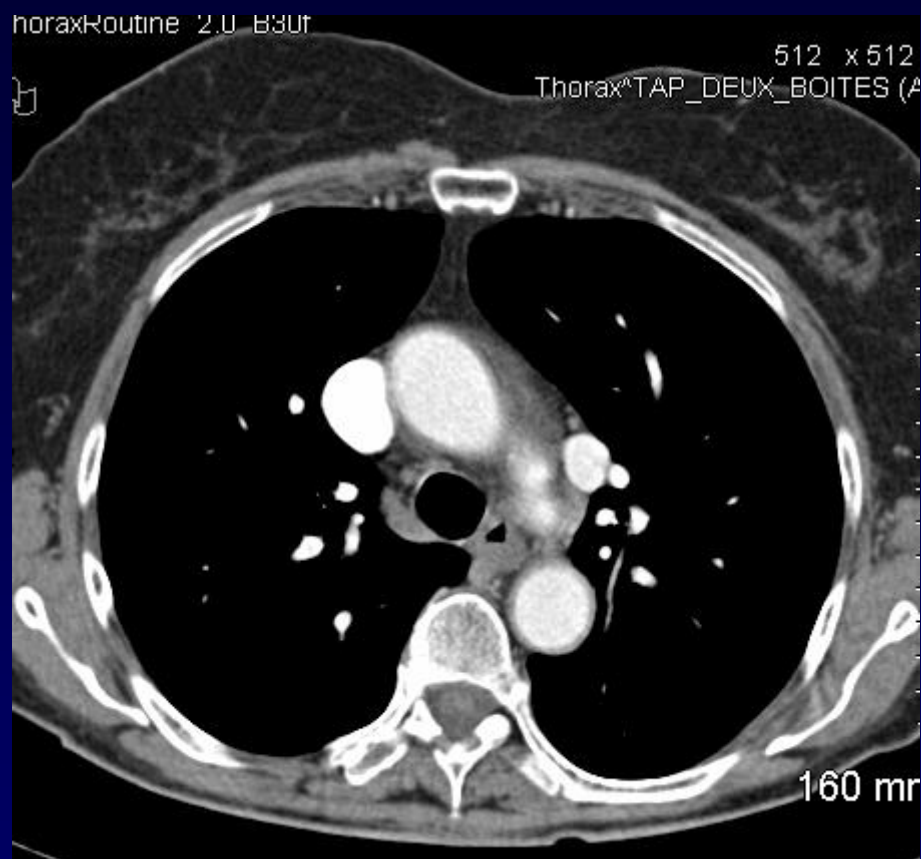


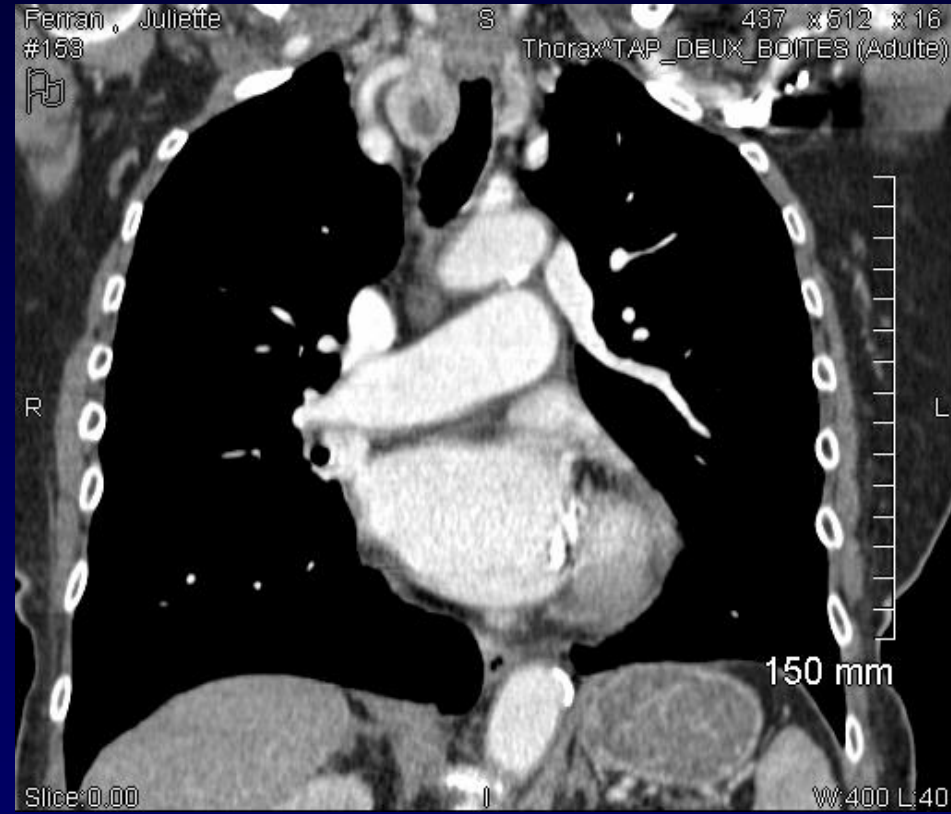
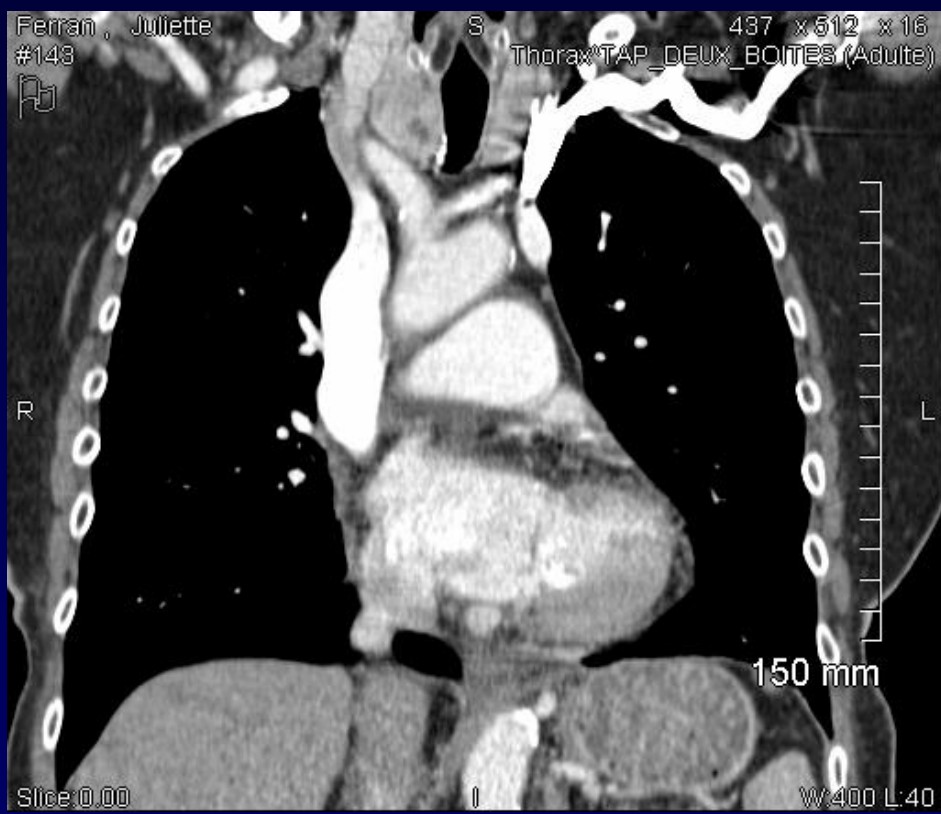
160 mm

Thorax^TAP_DEUX_BOITES (A



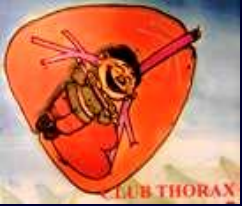160 mm







Diagnostic ?



Diagnostic

**RETOUR VEINEUX PULMONAIRE
ANORMAL LSG
SHUNT G – D...ASYMPTOMATIQUE**